

B. Shakibaie-M.

Socket and ridge preservation from the three-dimensional perspective

– A clinical study –

The healing process of the extraction socket results in a three-dimensional loss of volume of the alveolar ridge accompanied by crestolingual displacement of the mucogingival line. Combined hard and soft tissue resorptions of this kind can sometimes prevent the insertion of an implant in the prosthetically correct position without additional augmentative treatments. This prospective study evaluates in a split-mouth design the three-dimensional degree of preservation of the alveolar ridge following tooth extraction based on clinical and radiological examinations of 32 patients with 142 extractions with and without socket and ridge preservation (SP, RP) over a healing period of three to five months. In addition, the role of minimal invasive extraction techniques is closely considered in this context. Bio-Oss granules, Bio-Gide membrane and Stypro-Gelatine sponge were used for SP and RP depending on the indication. DVT, CT and coDiagnostiX software provided the basis for the three-dimensional radiological evaluation. The 3D radiological results obtained in the specified study period showed an approximately 65 % higher resorption rate in the control group without SP/RP than in the study group with SP/RP. The parameters of clinical width and thickness of the fixed gingiva and the alveolar ridge width can also be preserved significantly better in the study group than in the control group. A further noteworthy secondary effect is the approximately 50 % increase in local bone density after SP/RP, which positively influences the later primary stability of the implant. In the present study, after using SP/RP no additional augmentative treatment was necessary in more than 90 % of cases during subsequent implantation in correct 3D position. Summarising and assuming minimal invasive extraction, it can be concluded that the bony alveolar ridge and the covering fixed gingiva can be significantly better preserved three-dimensionally using the presented surgical protocol for SP and RP.

Keywords: Socket preservation, ridge preservation, minimal invasive tooth extraction, split mouth design, 3D-analysis, 3D-implant-planning, DVT, CT, soft tissue management, bone augmentation, implantation

Der Heilungsprozess der Extraktionsalveole führt zu einem dreidimensionalen Volumenverlust des Alveolarkamms mit gleichzeitiger krestolingualer Verschiebung der Mukogingivallinie. Solche kombinierte Hart- und Weichgeweberesorptionen können bisweilen eine Implantatinsertion in prothetisch korrekter Position ohne zusätzliche augmentative Maßnahmen verhindern. Die vorliegende prospektive Studie evaluiert in Split-Mouth-Design den dreidimensionalen Erhaltungsgrad des Alveolarkamms nach Zahntentfernung durch vergleichende klinische und radiologische Untersuchung von 32 Patienten mit 142 Extraktionen mit und ohne Socket- und Ridge Preservation über einen Heilungszeitraum von drei bis fünf Monaten. Zusätzlich wird die Rolle von minimalinvasiven Extraktionstechniken in diesem Zusammenhang näher durchleuchtet. Zur SP und RP wurden indikationsabhängig Bio-Oss Granulat, Bio-Gide Membran und Stypro-Gelatinevlies verwendet. DVT, CT und coDiagnostiX-Software bildeten die Basis für die dreidimensionale Röntgenauswertung. Die 3D-radiologischen Resultate zeigen im vorgegebenen Untersuchungszeitraum eine ca. 65%ig höhere Resorptionsrate der Kontrollgruppe ohne SP/RP als die Studiengruppe mit SP/RP. Auch die Parameter der klinischen Breite und Dicke der fixierten Gingiva sowie die Alveolarkammbreite lassen sich in der Studiengruppe signifikant besser erhalten als in der Kontrollgruppe. Ein weiterer bemerkenswerter Nebeneffekt ist die ca. 50%ige Erhöhung der lokalen Knochendichte nach SP/RP, welche die spätere Implantatprimärstabilität positiv beeinflusst. Nach Anwendung der SP/RP konnte im Rahmen der vorliegenden Untersuchung in über 90 % der Fälle auf eine zusätzliche augmentative Behandlung bei der späteren Implantation in korrekter 3D-Position verzichtet werden.

Zusammenfassend und die minimalinvasive Extraktion vorausgesetzt, kann festgehalten werden, dass sich der knöchernen Alveolarkamm und die deckende fixierte Gingiva nach dem vorgestellten Operationsprotokoll zur SP und RP dreidimensional signifikant besser erhalten lassen.

Schlüsselwörter: Socket Preservation, Ridge Preservation, minimalinvasive Zahnextraktion, Split-Mouth-Design, 3D-Analyse, 3D-Implantatplanung, DVT, CT, Weichgewebemanagement, Knochenaugmentation, Implantation

Introduction

Three-dimensional alveolar ridge atrophy develops predominantly within the first three months after a tooth extraction [1, 2]. The extent of the bone loss in terms of width is almost three times greater than in terms of height [3]. This resorption and remodelling associated breakdown process of alveolar bone simultaneously leads to a crestolingual displacement of the mucogingival borderline.

These conditions can render impossible both correct positioning of the implant and circumferential coverage of the implant with keratinised gingiva without extensive reconstructive treatments.

Three procedures for minimising or compensating this implantologically undesirable breakdown process have so far been described in the literature [4–6]:

- a) single-step treatment by immediate implantation
- b) multi-step treatment without reconstruction of the extraction socket with augmentation of the hard and soft tissue beforehand and/or simultaneously for subsequent implantation
- c) two-step treatment with reconstruction of the socket immediately after tooth extraction

The single-step treatment with immediate implantation requires a strict indication and is also technically demanding, because primary stable fixation of the implant is not possible in every extraction socket.

The multi-step approach with implantation five to nine months after extraction offers two notable advantages over the single-step procedure. Firstly, the bony remodelling processes in the alveolar ridge have reached a stable stage, allowing the implant to be inserted relatively easily, and secondly, the operation is performed with a keratinised closed mucosal cover. On the other hand, there is the serious disadvantage of the three-dimensional alveolar ridge atrophy mentioned above.

This article compares pre-implantological three-dimensional clinical and radiological results of two-step treatment with and without additional reconstructive treatments for the extraction socket (socket and ridge preservation) in a split mouth design.

	Total sample	Number of extracted teeth		
Patients	32	142		
	Number of extracted teeth	Minimal invasive extraction	Socket/ridge preservation	
Study group	85	yes	yes	
Control group	57	yes	no	

Table 1 Study structure with number of patients and extracted teeth.

Socket preservation (SP) is a term designating alveolar preservation measures achieved by immediate filling of the undamaged tooth socket with biomaterials (bone grafting material/collagen) or autologous bone following extraction.

The resorption of the alveolar structures is reduced firstly by stabilisation of the intra-alveolar blood coagulum and secondly by augmentation of the cavity.

If the bony extraction socket is damaged, the alveolar bone continuity is additionally restored with collagen membranes before/during its filling with biomaterials or autologous bone. This extension of the SP technique is called ridge preservation (RP).

Material and method

Since this project is a scientific evaluation of routine data of treated patients and the clinical use of approved products used after obtaining the patient's standard preoperative consent, the Ethics Committee of Westphalia-Lippe Chamber of Physicians did not consider that the study required a formal decision (Ref. No.: 2009–201-f-S).

32 patients referred to our practice between April 2006 and July 2008 participated in this internal practice study. 142 teeth were extracted in these patients. All the patients had an unremarkable medical history and were non-smokers. The age distribution was between 25 and 69 years. 24 patients were female and eight patients male. 15 patients had complex implant prosthetic case histories in which at least six teeth had been removed. The indication for extraction in these periodontally pre-treated patients was advanced marginal periodontopathy (125 teeth/88 %). The

remaining teeth were extracted because of a caries-related or endodontic indication (17 teeth/12 %). The indications for extraction were almost equally distributed between the control group and the study group.

After a detailed information session and obtaining the patients' informed consent, 57 minimally traumatic tooth extractions were performed without SP and RP in the control group. After 85 minimally traumatic extractions in the study group, the SP or RP techniques were used (Tab. 1).

In order to create as objective as possible preconditions, at least one extraction in the same patient and jaw was assigned to the test and control group in the split mouth design. In some of the jaws, several teeth were extracted per side (Fig. 1–3).

Because of the much poorer results meanwhile determined, the number of investigated sockets in the control group was limited to 57 on ethical considerations. The majority of extractions in both groups were in the lateral tooth region of the upper and lower jaw followed by the anterior tooth region of the upper jaw. The selection of teeth for assignment to the study and control group was left to the patients themselves by prior agreement, and therefore the random principle was applied. No significance level was established before starting the study. The surgical treatment protocol was identical in all patients of the respective investigational group (see surgical procedure). Three to five months post extraction the patients were examined pre-implantologically by three-dimensional CT (20 cases) or DVT (12 cases) and evaluated implantologically using coDiagnostiX software (IVS-Solutions, Chemnitz, Germany). To determine implantologically relevant bony and mucosal changes in the alveolar

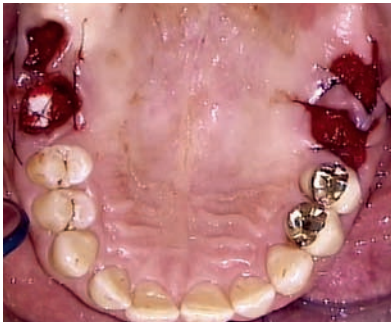


Figure 1 Occlusal view taken with a mirror immediately after removal of teeth 16, 17 in the control group and tooth removal with SP in region 26, 27 in the study group.

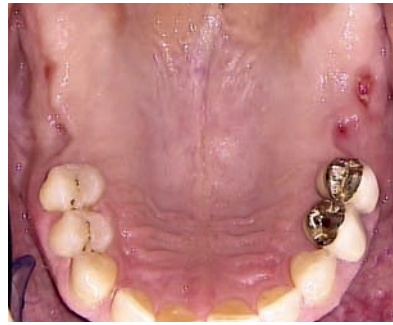

Figure 2 Occlusal view taken with a mirror three months after tooth removal 16, 17 in the control group and tooth removal with SP in region 26, 27 in the study group demonstrates comparatively the considerable three-dimensional tissue loss.

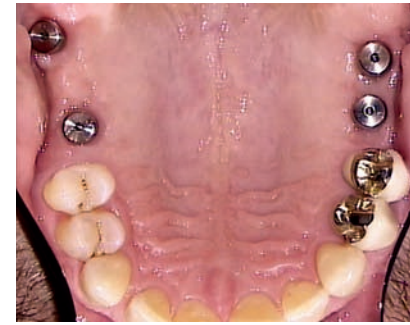

Figure 3 Occlusal view taken with a mirror eight months post implantation and external sinus lift in regions 16, 17, 26 and 27 (Camlog Screw-Line implants and Camlog cylindrical gingiva former) shows the clearly better initial prosthetic situation after using SP, a regular implantation was not possible in region 17 due to advanced resorption despite optimal 3D-analysis.

Fig. 1-3: Shakibaie-M.

ridge post extraction, immediately after the extraction the clinical parameters of crestal width of the alveolar ridge (AW1), measured as transverse alveolar diameter immediately post extraction, and the width of the fixed gingiva (WFG1), measured vertically from the vestibular alveolar margin to the mucogingival borderline, were determined on each free socket in all patients. In addition, the thickness of the vestibular keratinised gingiva was determined 1 mm submarginally through penetration with a periodontal probe (TFG1). Three to five months post extraction – after 3D radiological examination – these parameters were measured again and recorded with AW2, WFG2 and TFG2. The measurements for AW and WFG were also performed with the aid of a periodontal probe to an accuracy of 0.5 mm (markings). The differences in the above parameters (DAW, DWFG and DTFG) from each investigational group were analysed statistically.

From the three-dimensional investigations, the following parameters were additionally determined for the former extraction socket with the aid of the coDiagnostiX software:

1. Mean transversal alveolar ridge width (MTA), separate measurement in the two investigational groups
2. Mean axial alveolar ridge width (MAA), separate measurement in the two investigational groups

3. Mean local bone density (MBD), measured as a mean value in both investigational groups in axial and transversal views in Hounsfield units.

The MTA value was measured in each case as the highest implantologically relevant width value in the transversal view with the aid of a parallel to the masticatory plane. The MAA value was measured in each case as the highest implantologically relevant width value on the axial plane with the aid of a perpendicular to the alveolar ridge line. Both values were recorded to an accuracy of 0.1 mm with the measurement module of the coDiagnostiX software. Differential values were rounded from 0.5 mm in each case. The Hounsfield units for the MBD were measured with the coDiagnostiX software.

Surgical procedure

Minimally invasive tooth extraction

Following preoperative nerve block and infiltration anesthesia in the conventional manner, the gingival circular ligament was severed sharply with a microelevator or microscalpel (DCV, Seitingen-Tuttlingen, Germany). With a favourable anatomical shape of the socket and a broad desmodontal gap,

the same instruments can be used for dissection of Sharpey's fibres. Experience shows that this is more commonly the case with maxillary cancellous alveolar bone than in the mandible. If the tooth offers a sufficient coronal retention surface for the extraction forceps (DCV, Seitingen-Tuttlingen, Germany), the extraction is then performed cautiously and steadily for single-rooted teeth without using levers – to avoid horizontal dislocation movement – by executing vertical and slightly rotating movements. If a crown fracture is present at this stage, the tooth is completely decapitated and if possible – assuming periodontally healthy and restoration-free adjacent teeth – extracted using the Benex-System (DCV, Seitingen-Tuttlingen, Germany). If the preconditions for the use of the Benex-System are not present, the root residue can be segmented vertically in the form of an intra-alveolar tooth extraction [7], in order to continue the extraction with fine levers of the Xtool-System (DCV, Seitingen-Tuttlingen, Germany). In special cases a combination of the above techniques is also conceivable.

For multiple-rooted teeth, vertical separation of the individual roots is always performed. After cautious dislocation from vertical direction, the individual root segments are extracted as required using retained root forceps. Strict attention is devoted to ensuring that ho-

horizontal dislocations are avoided as far as possible. The aim of this sometimes demanding minimally invasive extraction is to spare the structures necessary for subsequent low-resorption healing, such as the vestibular bone lamella, intra-alveolar and interproximal bone septa.

In the control group, after the minimally invasive tooth extraction and socket cleaning, the tooth socket was simply filled with a Stypro-Gelatine sponge (Curasan, Kleinostheim, Germany) and closed with a situation suture 4/0 and 5/0 Seralon needle-thread combination (Serag-Wiessner, Naila, Germany). Teeth whose extraction was associated with loss of the vestibular bone lamella or which even required osteotomy were not included in the control group.

Socket and ridge preservation (SP and RP)

When the goal of minimally invasive tooth removal – preserving the bony socket as completely as possible – was achieved during this study, after careful curettage and irrigation (physiological saline solution) the socket was filled with Bio-Oss granules (Geistlich Pharma AG, Wolhusen, Switzerland) of size 1–2 mm and slightly condensed equicrestally. The alveolar duct was then sealed with cut-to-size Stypro Gelatine sponge. The procedure was completed with wound fixation with situation sutures using 4/0 and 5/0 Seralon needle-thread combinations [21] (Fig. 1). The gelatine sponge prevented detachment of the Bio-Oss granules from the socket and accelerated crestal healing of the keratinised gingiva. In these cases the implantation was performed after an average of three months, 3D radiographic evaluation and at least 14-day complete closure of the keratinised gingival cover over the socket (Fig. 2–3).

If the socket showed bone deficits despite/after minimally invasive extraction, its morphology was determined by close inspection. In this case too, care was taken during the extraction to ensure that as many bone walls of the socket as possible were preserved in order to improve the blood supply to the xenogenic augmentation material and thereby reduce the rate of resorption. In such alveolar bone defects, which are usually present at vestibular sites, both block transplants and RP are indicated.

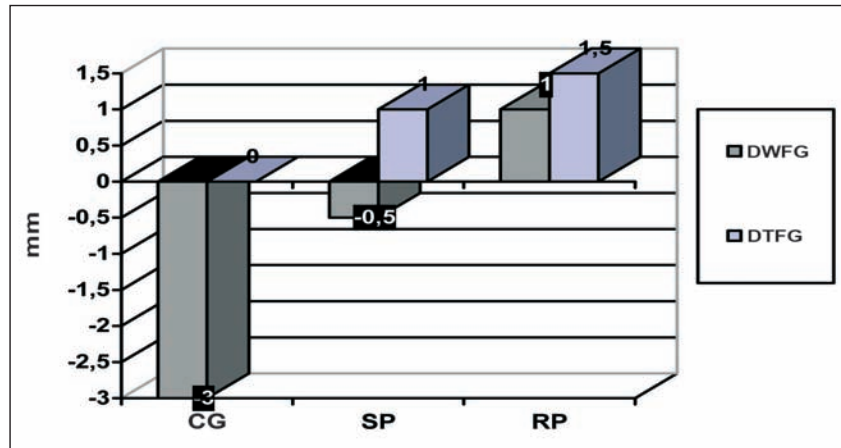


Figure 4 Clinical change in the width and thickness of the crestovestibularly fixed gingiva in the control group (CG), after using SP and RP three to five months post-extraction. DWFG: Difference in the width of the fixed gingiva; DTFG: Difference in the thickness of the fixed gingiva.

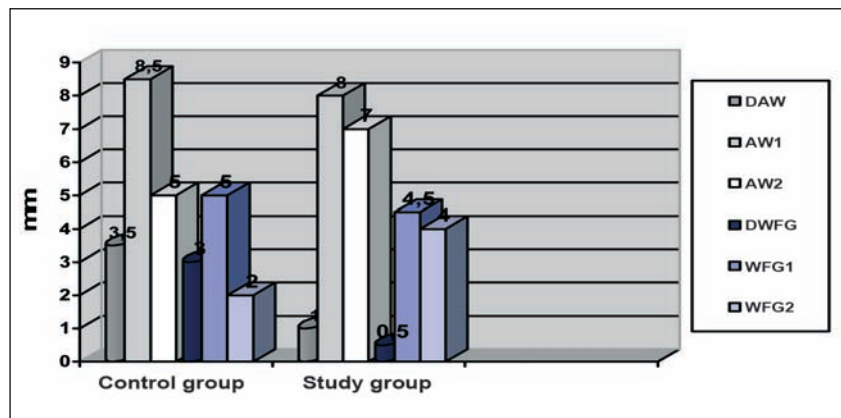


Figure 5 Comparison of clinical changes in the alveolar ridge in the control and study group. DAW: Difference in alveolar ridge width (pre-extraction and three to five months post-extraction). AW1: Mean alveolar ridge width value post-extraction. AW2: Mean alveolar ridge width value pre-implantation. DWFG: Difference in the width of fixed gingiva (pre-extraction and three to five months post-extraction). WFG1: Mean width value of the fixed gingiva post-extraction. WFG2: Mean width value of the fixed gingiva pre-implantation.

Besides the shortened treatment period and reduced trauma, the advantage of ridge preservation compared to block graft transplantation lies mainly in the avoidance of displacement of the mucogingival borderline, from which the later implantation with keratinised soft tissue formation benefits.

Similarly to socket preservation, in ridge preservation – after careful creation of a mucoperiosteal flap and exposure of the alveolar defect – the cavity of the residual socket was built up with coarse particulate Bio-Oss granules. Defect coverage was then performed, depending on the gingival biotype, using at least two or more layers of Bio-Gide

membrane (Geistlich Pharma AG, Wolhusen, Switzerland). The first Bio-Gide membrane was applied with an approximately 3 mm defect overlap, and the following layers projected by at least 1 mm over the first membrane thereby creating an additional adhesion surface with the surrounding bone. With this procedure, the superimposed membrane layers were sufficiently stable so that no additional pin fixation was necessary. The Bio-Gide membrane was always drawn crestally completely over the socket towards palatal and fixed subperiosteally [21]. It therefore remained orally exposed in the socket entrance region and was resorbed during second-

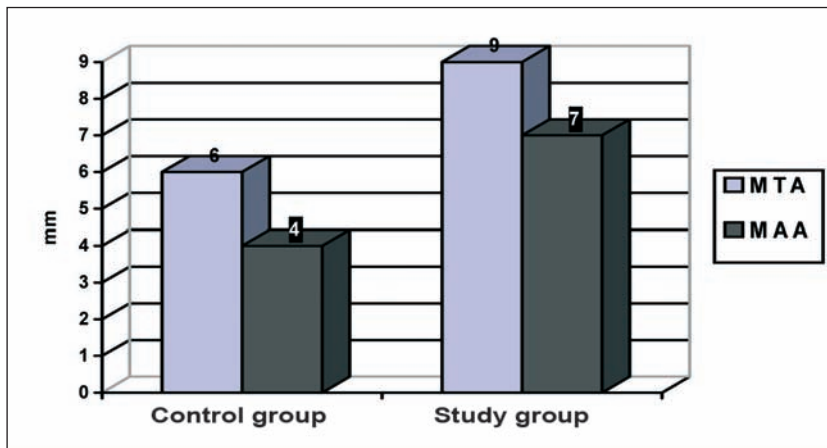


Figure 6 Comparison of the absolute three-dimensional radiological alveolar ridge measurements in the control and study group. MTA: Mean transversal alveolar ridge width (pre-implantation, three to five months post-extraction). MAA: Mean axial alveolar ridge width (pre-implantation, three to five months post-extraction).

dary wound healing. Wound closure was performed without periosteal slitting. The patients then received a pontic shaped temporary tooth replacement in this region [21]. The implantation and 3D-radiographic examination were performed on average after four months. In these cases too, the duration of complete crestal healing of the keratinised gingiva (at least 14 days) determined the exact time of implantation.

Results

Postoperative healing was uncomplicated after all extractions and socket preservation treatments. Great importance was attached to the cautious use of a microelevator or microscalpel to sever the circular periodontal ligament – especially in the approximal region – before the extraction. With this approach, aesthetically compromising injuries to the marginal gingiva could be largely avoided and wound healing accelerated. Despite new developments for vertical minimally invasive tooth extraction such as periostomes, Benex-System, Xtool-System and vertical segmentation of multi-rooted teeth, horizontal dislocation of dental roots could not be avoided in all cases. This was mainly the case when atypical root formations, divergent root tips, ankyloses, longitudinal root fractures or root canal obliterations were present which prevented anchoring of the Benex-System. If horizontal

lever dislocation was unavoidable, care was taken to ensure that this was only approximal to prevent fracturing of the vestibular bone lamella. This was the anatomically decisive structure which decided whether the indication was for SP or RP. In almost all cases the crestovestibular width and thickness values of the fixed gingiva were better after the use of RP than after the use of SP (Fig. 4).

The keratinised gingival growth was visually apparent even without the described periodontal probe measurement, since the anatomically convex alveolar ridge contour was substantially exceeded. The gingival thickness could be measured by three-dimensional radiography especially in the crestal region as the distance between the radiopaque 3D splint base and the bone surface in the transversal view. The radiological values were found to correlate with the clinically measured values. The mean width of the fixed gingiva was also better preserved in the study group with a decrease of 0.5 mm compared to the initial value than in the control group with a decrease of 3.0 mm (Fig. 4).

The mean resorption of the clinically determined alveolar ridge width was 3.5 times higher in the control group than in the study group (Fig. 5). The mean resorption of the clinically determined width values of the fixed gingiva was 6 times higher in the control group than in the study group (Fig. 4 and 5). A greater difference was observed after RP (4 mm) than after SP (3 mm). The radio-

logically determined mean axial alveolar ridge width was about 85 % higher in the study group than in the control group (Fig. 6–7). A similar situation was observed for the transversal alveolar ridge width which was 50 % better preserved in the study group than in the control group (Fig. 6, 8–9).

Overall, the bony study parameters (DAW, MTA, MAA) showed slightly higher resorption after RP than after the use of SP. The bone density also decreased somewhat during RP. In the study group, the radiologically measured bone density was much higher than in the control group (Fig. 7–10).

For later implantation in the patients of the control group, corresponding to the above results augmentative treatments were required much more often than in the study group. Eight augmentative treatments were counted in the study group (9.4 %). In the control group, on the other hand, 33 augmentation interventions were needed to make the alveolar ridge implantable (58 %) (Fig. 11).

Discussion

Tooth extraction is inevitably followed by progressive three-dimensional resorption in the alveolar ridge. The greater part of this combined hard and soft tissue atrophy takes place in the first twelve weeks post extraction [1, 2]. Consequently, bony and connective tissue augmentations are necessary to allow prosthetically correct positioning of implants at such sites [8, 9]. This means not only further operative procedures and additional costs but above all a longer treatment period. Although the loss of alveolar ridge width can in most cases be reliably reconstructed with such a multi-step treatment approach, because of the time delay from the extraction to the implantation (5–9 months) there is a prosthetically counterproductive resorption of alveolar ridge height which only becomes apparent later compared to the alveolar ridge width resorption following tooth loss [10, 11, 16].

To reduce the trauma for the patient and shorten the treatment time, various concepts for the treatment of the extraction socket have been presented in the past. These methods range from covering the extraction socket with resor-

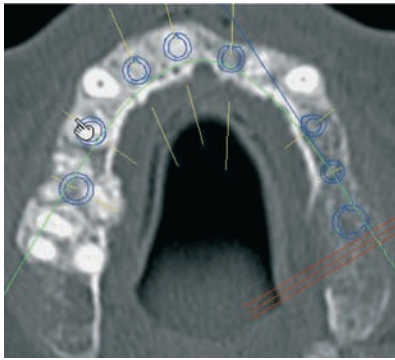


Figure 7 Axial view of upper jaw in status four months after simple tooth extraction in region 21, 24, 25, 26 (control group) and tooth extraction with SP/RP in region 11, 12, 14, 16.

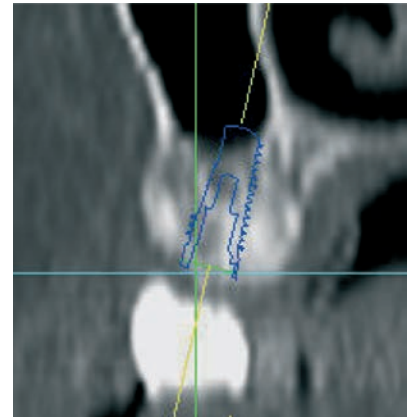
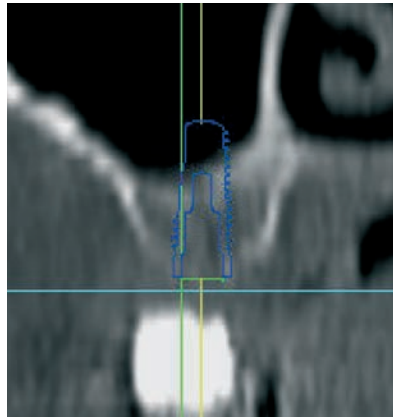


Figure 8–9 Transversal view of region 14 (study group) right and region 24 (control group) left for comparison four months post-extraction, identical case as in Figure 28.

Fig. 1-9: Shakibaie-M.

able and non-resorbable membranes to filling them with resorbable and non-resorbable bone replacement material with or without autologous bone combined with the use of gelatin sponge or autologous mucosa (connective tissue) graft [2, 7, 9, 12, 13, 15].

Promising attempts have also been made to regenerate the empty tooth socket with growth factors (BMP-2) [20], although these have not yet been able to establish themselves under economic aspects. All these techniques without exception presuppose minimally invasive extraction to ensure the most complete possible preservation of the socket.

The split mouth design used in the present study made prior randomisation of patients unnecessary. Although no significance limit for the later statistical analysis was established before starting the study, after conclusion of the study the results were so conspicuously different that the probabilities can be assumed to be 0.000. Because of the unequivocal nature of the results, an additional statistical test was also not performed.

The fact of the uneven distribution of the number of sockets in the two investigational groups which, as explained above, had an ethical background, could have slightly influenced the statistical value of the results. The results clearly show that when the continuity of the socket is interrupted because of prior inflammatory processes, surgical interventions for tooth preservation or even as a result of extraction, the three-

dimensional alveolar ridge atrophy is more pronounced than when the socket is fully preserved. Timely and per-protocol performed RP is structure-preserving in such cases, but does not reach the values of SP when the tooth socket is completely present.

It is therefore recommended to select a minimally invasive (vertical) extraction strategy before each tooth extraction where the later gap is to be treated with an implant. This can be accomplished using fine periostomes and luxators, vertical segmentation of tooth root(s) or/and assistive devices for vertical extraction like the Benex-System. The aim is then always to spare the circumferential bone boundary of the extraction socket as well as the alveolar interproximal and interradiolar bone septa. Only in this way can the local blood circulation of the preserved residual anatomical structures and the bone grafting material introduced into the tooth socket be rendered optimal in terms of future wound healing.

Filling the extraction socket with a non-resorbable bone grafting material is certainly an interfering factor for normal wound healing in this region. This is why not yet fully osseointegrated bone grafting granules are still identifiable even at the time of implantation three to five months post extraction. Clinically apparent disorders of wound healing, however, were not observed at any time during this study. Jung et al. also come to the same clinically good result after filling the

extraction socket with Bio-Oss Collagen [13]. Evidently it is this non- or late resorbability of the material, which is the guarantor of volume preservation of the alveolar ridge after extraction. This effect has been demonstrated in animal histological studies by Araujo et al., although with the proviso that the volume preservation achieved with SP could be resorbed again in the absence of later loading of the bone by an implant. [14].

Similarly significant bone preservation following tooth extraction using Bio-Oss is also reported by Nevins et al. in their prospective comparative study in maxillary anterior teeth [19]. The three-dimensional radiological and significantly better alveolar ridge dimensions after SP and RP seen in the present study correlate with the results of Strietzel and Shakibaie-M. after the use of membranes [2] and those of Schropp et al. [1] with the additional difference that in the protocol presented here the bone density and the keratinised soft tissue profile appear much better. Particularly the favourable development of the width and thickness of fixed gingiva according to the method described could in the long term offer a new, more atraumatic alternative method for harvesting mucosal or connective tissue grafts for covering the filled socket [7, 9, 13].

The differences between the results of the clinical and radiological measurements are worth mentioning. Despite a correlation, the clinical difference values of the alveolar ridge width are considera-

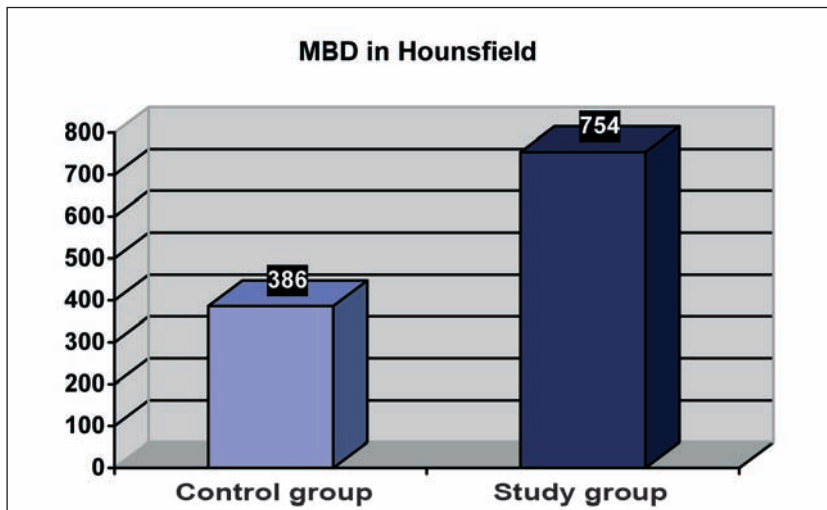


Figure 10 Comparison of pre-implantation local mean bone density in the control and study group three to five months post-extraction.

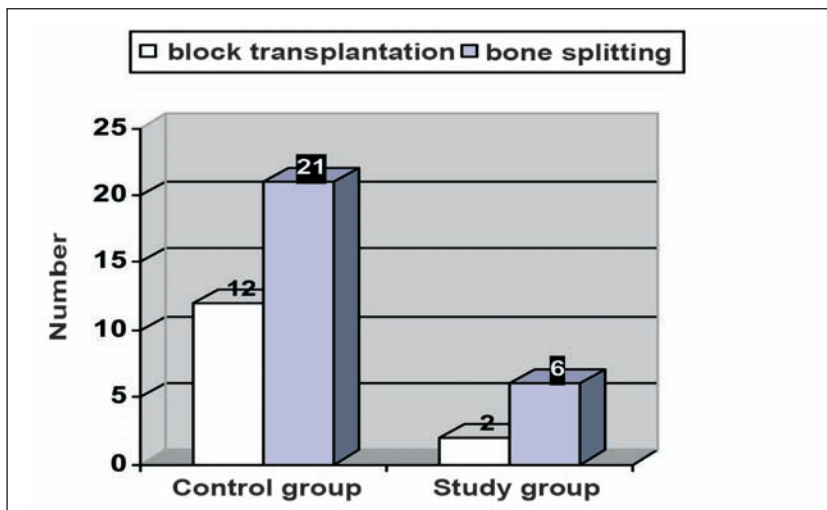


Figure 11 Comparison of number of necessary augmentative treatments at the time of implantation three to five months post-extraction in the control and study group.

bly higher compared to the 3D-radiological difference values. This is firstly linked to the fact that 3D-radiological examinations were only preimplantological and therefore the dimensional changes in the control sockets in the decisive weeks after the extraction were not taken into account. On the other hand, the clinical measurements were also influenced by the different dimensions of the keratinised gingiva and the differing course of the mucogingival line.

A conceivable cofactor for the slightly higher local bone resorption and lo-

wer bone density after RP compared to SP will certainly be the poorer blood circulation due to the absent socket walls. Experience gained in this study makes it appear advisable to schedule an average one month longer healing phase in the case of RP compared to SP. Although a somewhat higher vertical resorption may then be expected, at the same time there will be a higher bone density and a more stable vestibular bone wall. It should be noted that depending on the degree of loss of alveolar bone in RP it may be necessary to reduce the chosen

implant diameter because of the smaller amount of bone available or that an osteoplastic extension of the implant bed may be necessary.

The observation of the crestovestibular gingival thickening in RP after the use of multi-layer collagen membrane four to five months post extraction is certainly interesting and implantologically favourable. However, the histological principles of this phenomenon and the sustainability prognosis of the mucosa mentioned will have to remain the subject for further scientific studies.

SP and RP according to the protocol presented are in surgical terms comparatively easy to perform and low-risk interventions which not only shorten the treatment time and reduce traumas and costs due to the absence of demanding augmentative treatments, but also increase the quality and durability of the prosthetic supraconstruction (Fig. 1–3).

Even if – similarly to osseointegrated implants in the GBR regenerated bone [17, 18] – it may be assumed to be the case, the long-term stability of augmented sockets due to SP and RP post implantation will require further scientific investigation.

Note: All clinical pictures in this article were taken with the OPMI (operating microscope). (Source: Dr. B. Shakibaie-M., Rheda-Wiedenbrueck, Germany).

Translated original studie: B. Shakibaie-M.: Socket und Ridge Preservation aus dreidimensionaler Sicht – Eine klinische Studie. *Z Zahnärztl Implantol* 2009; 25:369–377

Mit freundlicher Genehmigung Deutscher Aertzte-Verlag GmbH.

Address for correspondence:

Dr. Behnam Shakibaie-M.:
 Specialised clinic of minimally invasive
 & microscopically guided implantology
 Hauptstrasse 124
 33378 Rheda-Wiedenbrueck
 Germany
 E-Mail: drbshakibaie@yahoo.com

References

1. Schropp L, Wenzel A, Kostopoulos L, Karring T: Bone healing soft tissue contour changes followig single-tooth extraction: A clinical and radiographic 12-month prospective study. *Int J Periodontics Restorative Dent* 2003;23: 313–323
2. Strietzel FP, Shakibaie-M B: Der Einsatz des TefGen-FD®-Membran zum Erhalt des Alveolarkamms nach Zahnextraktionen: eine klinische Studie. *Dtsch Zahnärztl Z* 1998;12:883–886
3. Araujo MG, Lindhe J: Dimensional ridge alterations following tooth extraction. An experimental study in the dog. *J Clin Periodontol* 2005;32: 212–218
4. Hämmerle C, Chen S, Wilson T: Konsensuserklärungen und empfohlene klinische Verfahren zum Einsetzen von Implantaten in Extraktionsalveolen. *Implantologie* 2006;14(4):335–338
5. Glauser R, Zembic A, Hämmerle CHF: A systematic review of marginal soft tissue at implants subjected to immediat loading or immediat restoration. *Clin Oral Impl Res* 2006;17(Suppl.2):82–92
6. Zuhr O, Fickl S, Wachtel H, Bolz W, Hürzeler MB: Die Versorgung der Extraktionsalveole aus prothetischer Sicht – Detailspekte für ästhetisch relevante Situationen. *Implantologie* 2006;14(4):339–353
7. Terheyden H: Rekonstruktion und verzögerte Sofortrekonstruktion der Extraktionsalveole. *Implantologie* 2006; 14(4):365–375
8. Hämmerle CHF, Jung RE, Yaman D, Lang NP: Ridge augmentation by applying bioresorbable membranes and deproteinized bovine bone mineral: a report of twelve consecutive cases. *Clin Oral Implants Res* 2008;19:19–25
9. Terheyden H, Iglhaut G: Chirurgische Versorgung der Extraktionsalveole. *Z Zahnärztl Impl* 2006;22:42–45
10. Simion M, Frontane F, Rasperini G, Maiorana C: Vertical ridge augmentation by expanded-polytetrafluorethylene membrane and a combination of intraoral autogenous bone graft and deproteinized anorganic bovine bone (Geistlich Bio-Oss). *Clin Oral Implants Res* 2007;18:620–9
11. Araujo M, Cardaropoli G, Hayacibara R, Sukekava F, Lindhe J: Healing of extraction sockets and surgically produced – augmented and non-augmented – defects in the alveolar ridge. An experimental study in the dog. *J Clin Periodontol* 2005;32:435–440
12. Weng D, Böhm S: Simplify your Augmentation – Was bei der Extraktion zu beachten ist, damit die Implantation einfach wird – Ein Konzept zur Versorgung von Extraktionsalveolen vor der Implantatinserion. *Implantologie* 2006;14(4):355–363
13. Jung RE, Siegenthaler DW, Hämmerle CH: A soft tissue punch technique. *Int J Periodontics Restorative Dent* 2004;24: 545–553
14. Araujo M, Linder E, Wennström J, Lindhe J: The Influence of Bio-Oss Collagen on Healing of an Extraction Socket: An Experimental Study in the Dog. *Int J Periodontics Restorative Dent* 2008;28: 123–135
15. Lekovic V, Camargo PM, Klokkevold PR: Preservation of alveolar bone in extraction sockets using bioabsorbable membranes. *J Periodontol* 1998;69: 1044–1049
16. Simion M, Trisi P, Piatelli A: Vertikal ridge augmentation using a membrane technique associated with osseointegrated implants. *Int J Periodontics Restorative Dent* 1994;14:496–511
17. Nevins M, Mellonig JT, Clem DS, Reiser GM, Buser DA: Impants in regenerated bone: Long-term survival. *Int J Periodontics Restorative Dent* 1998;18(1): 34–35
18. Buser D, Dula K, Lang NP, Nyman S: Long-term stability of osseointegrated implants in bone regenerated with membrane technique. 5-year results of a prospective study with 12 implants. *Clin Oral Implants Res* 1996;7:175–183
19. Nevins M, Camelo M, De Paoli S, Friedland B, Schenk RK, Parma-Benfenati S, Simion M, Tinti C, Wagenberg B: A Study of the Fate of the Buccal Wall of Extraction Sockets of Teeth with Prominent Roots. *Int J Periodontics Restorative Dent* 2006;26:19–29
20. Fiorellini J, Howell TH, Cochran D: Randomized staudy evaluating recombinant human bone morphogenic protein-2 for extraction socket augmentation. *J Periodontol* 2005;76:605–613
21. Shakibaie-M B: Socket und Ridge Preservation. *Dent Mag* 2009;2:24–33